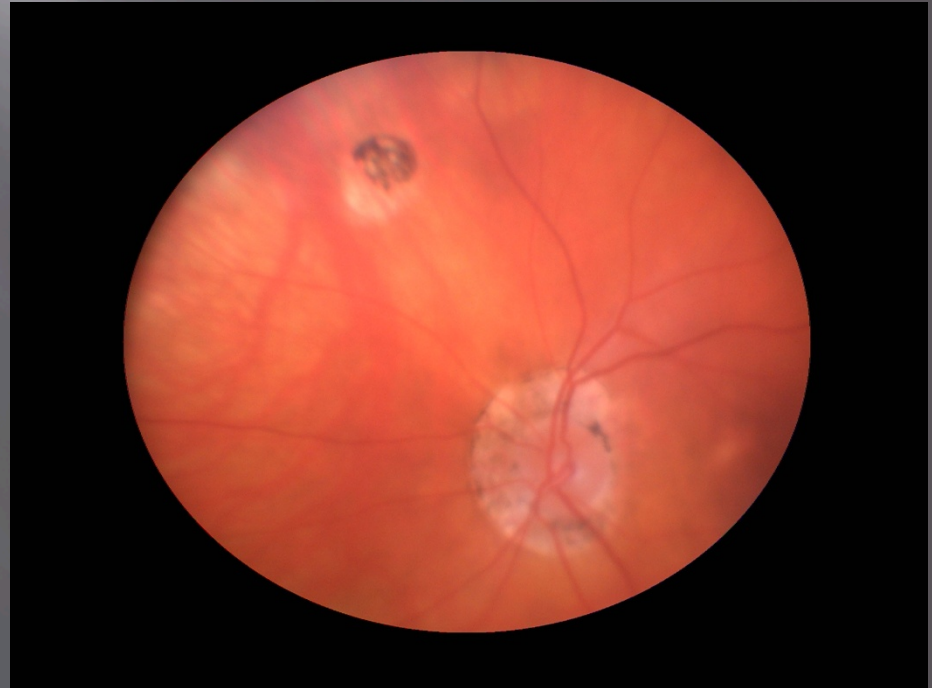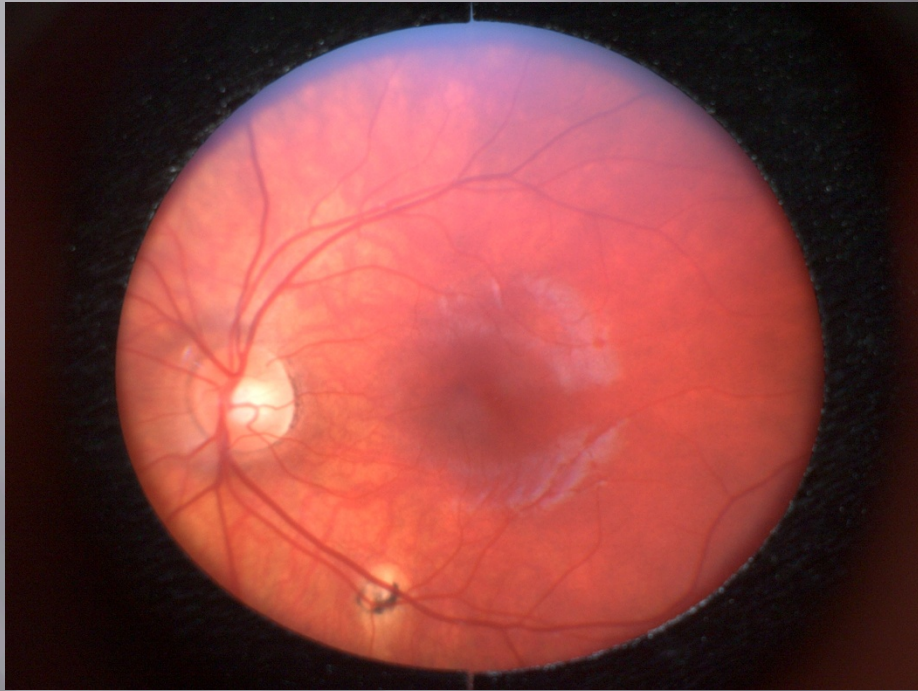

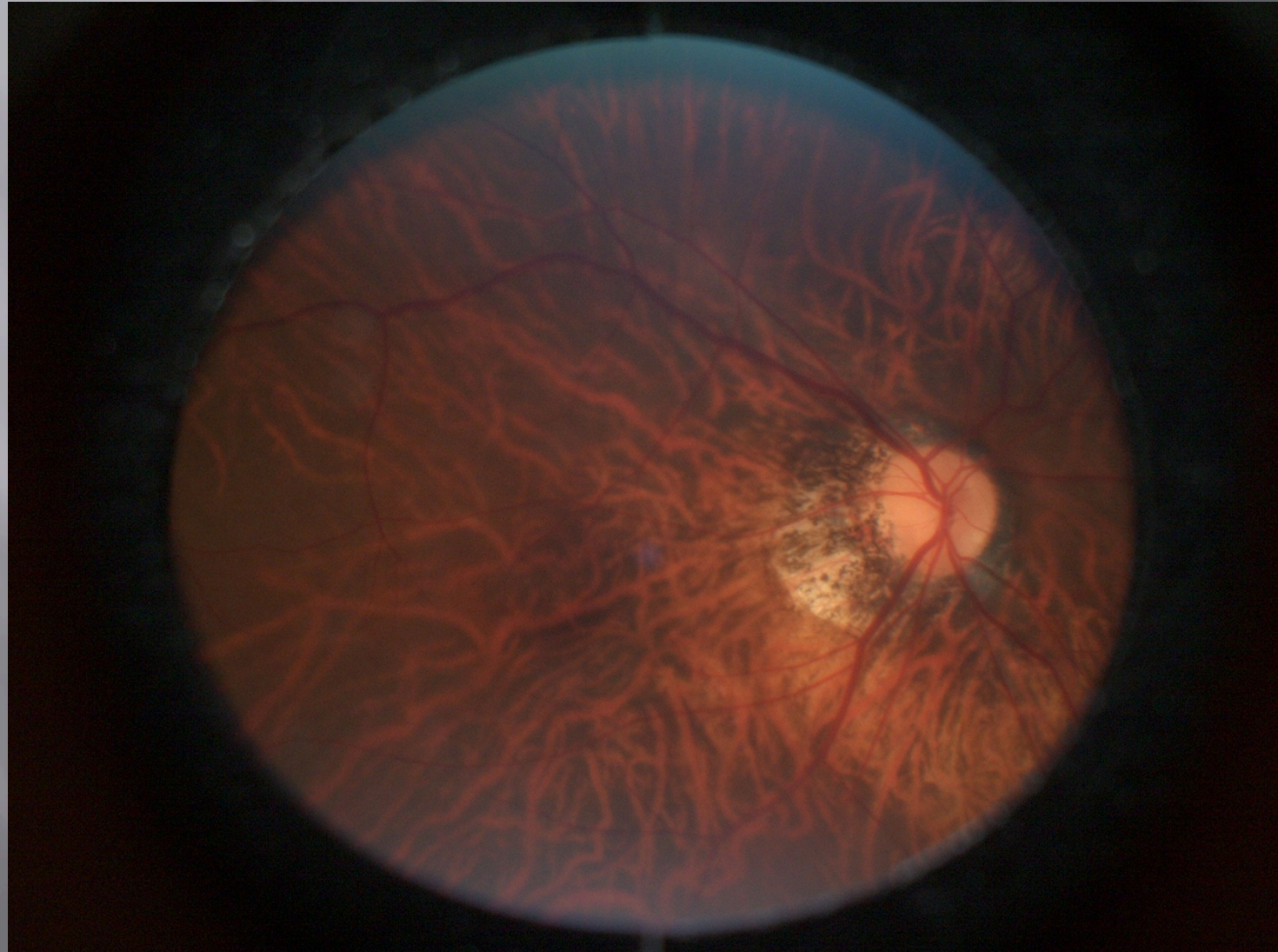
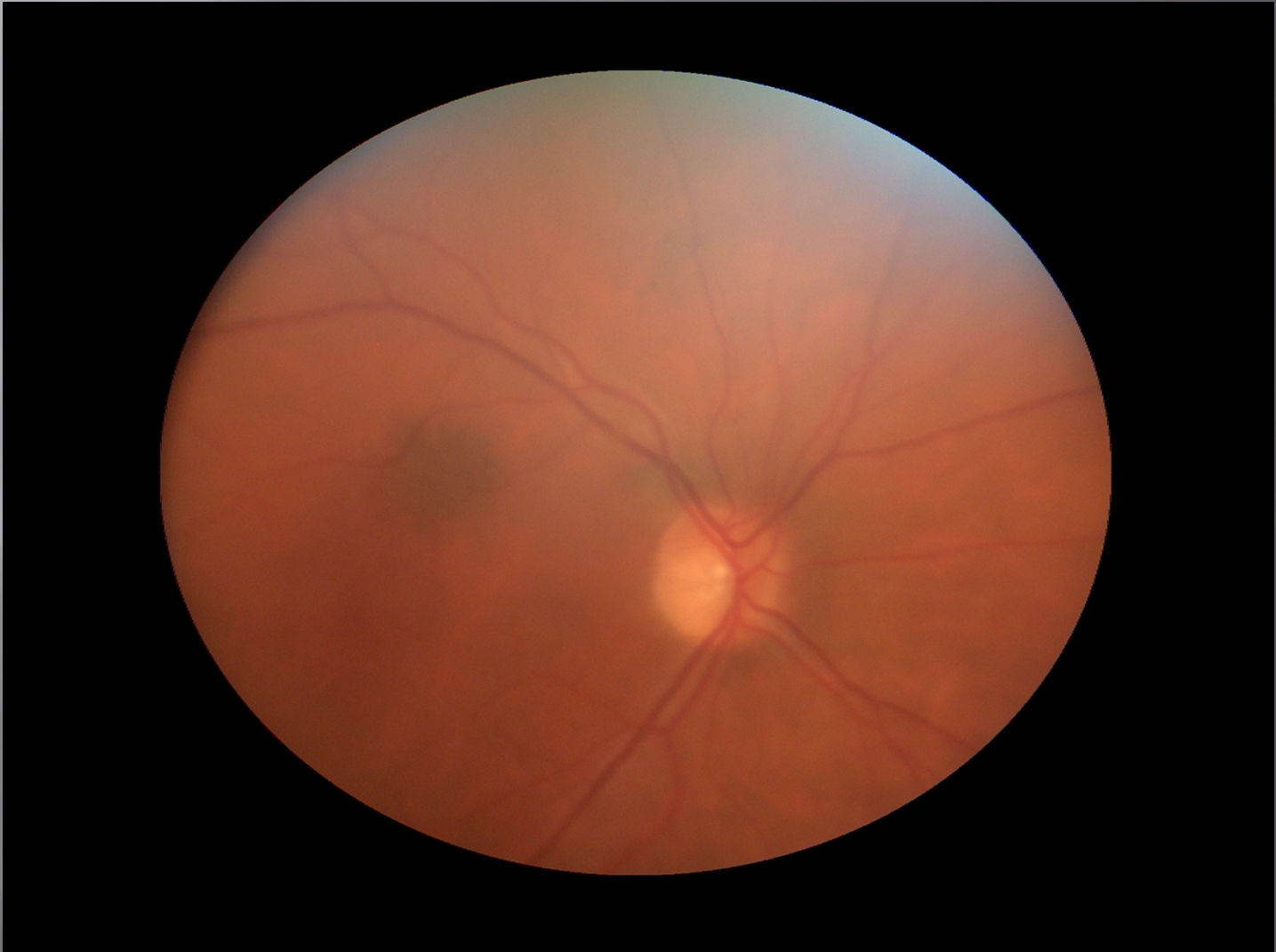
HISTOPLASMA SCARS



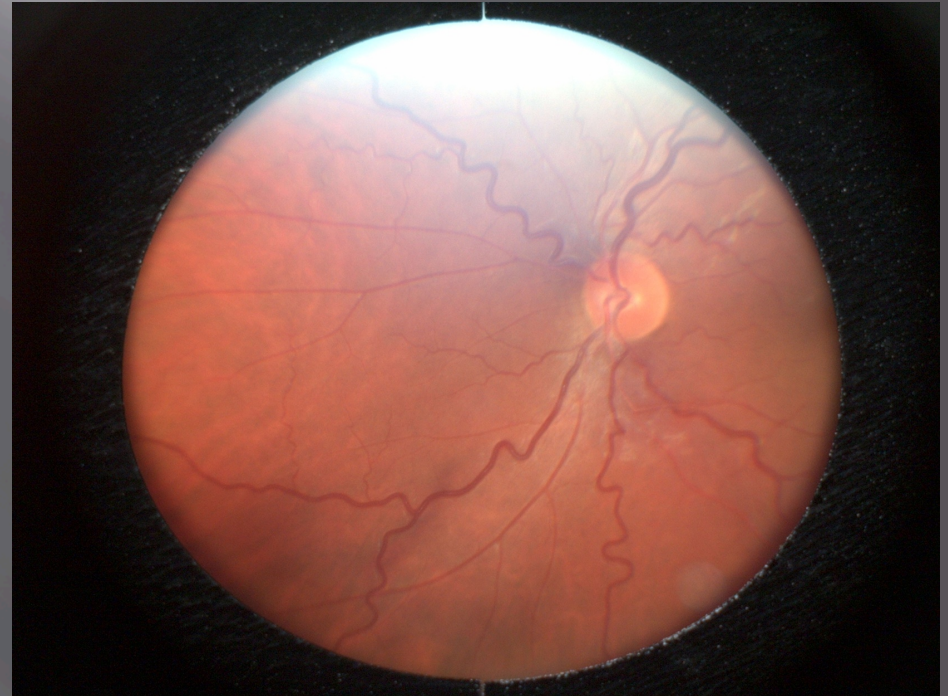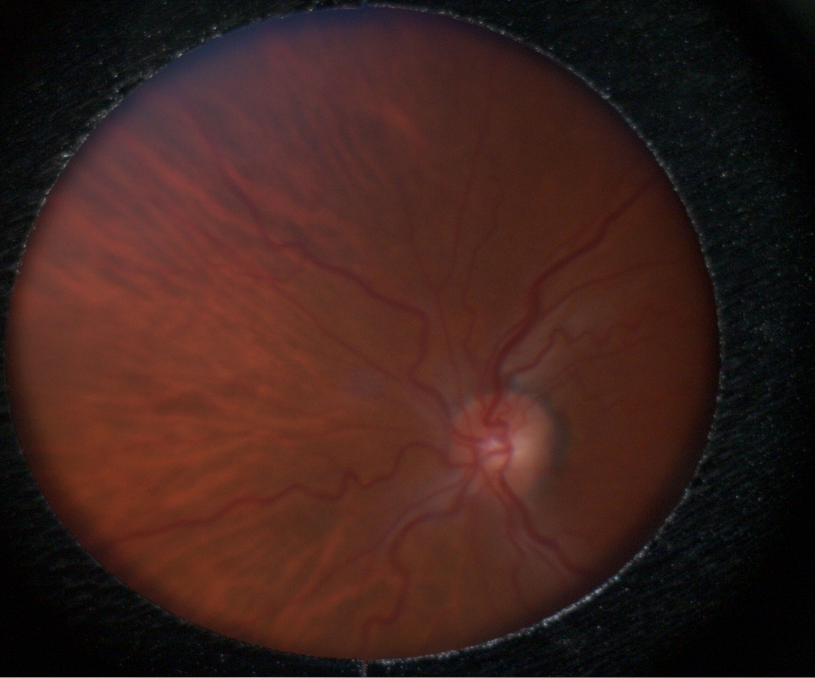
Myopic Atrophy



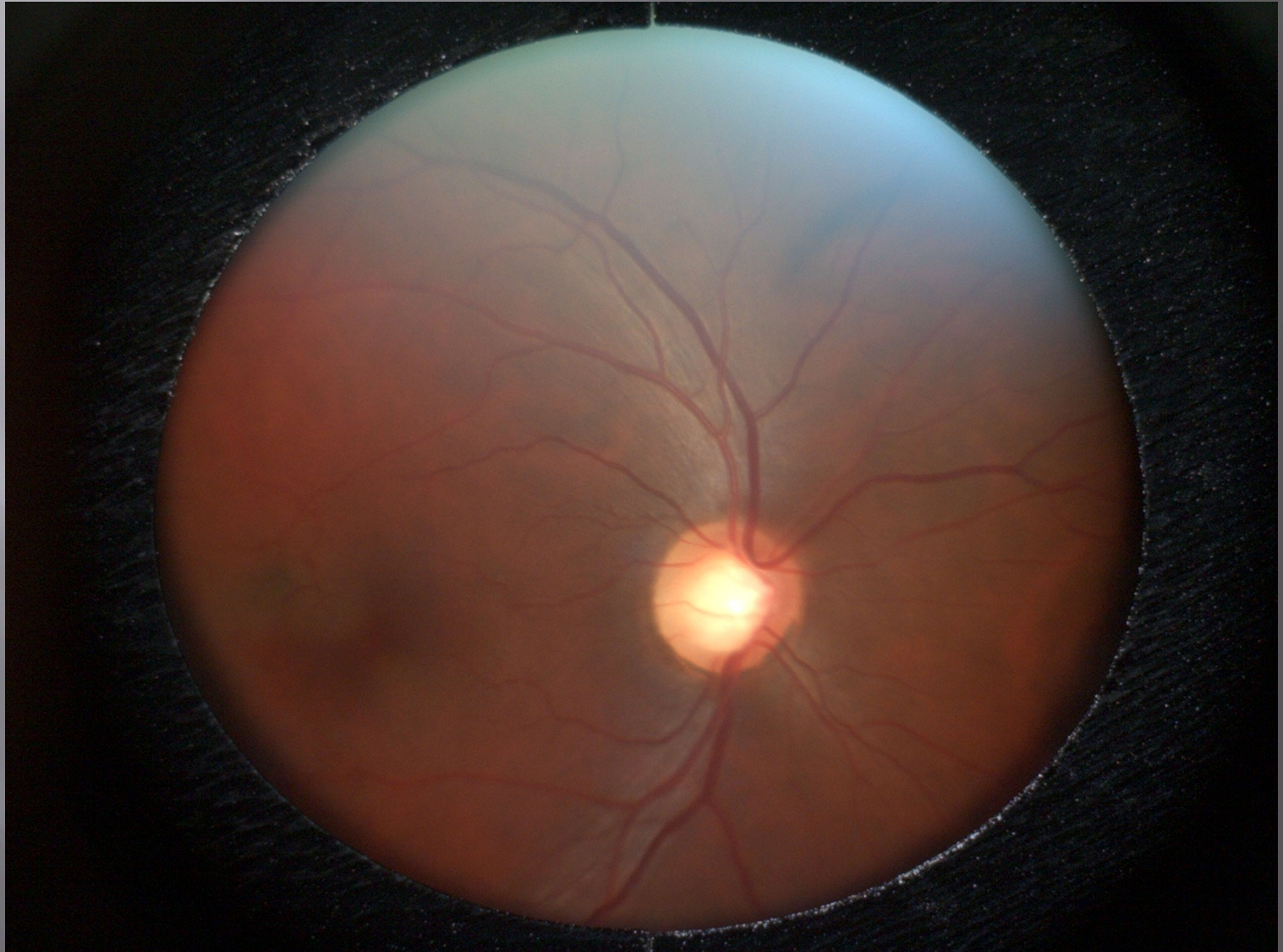Choroidal Nevi



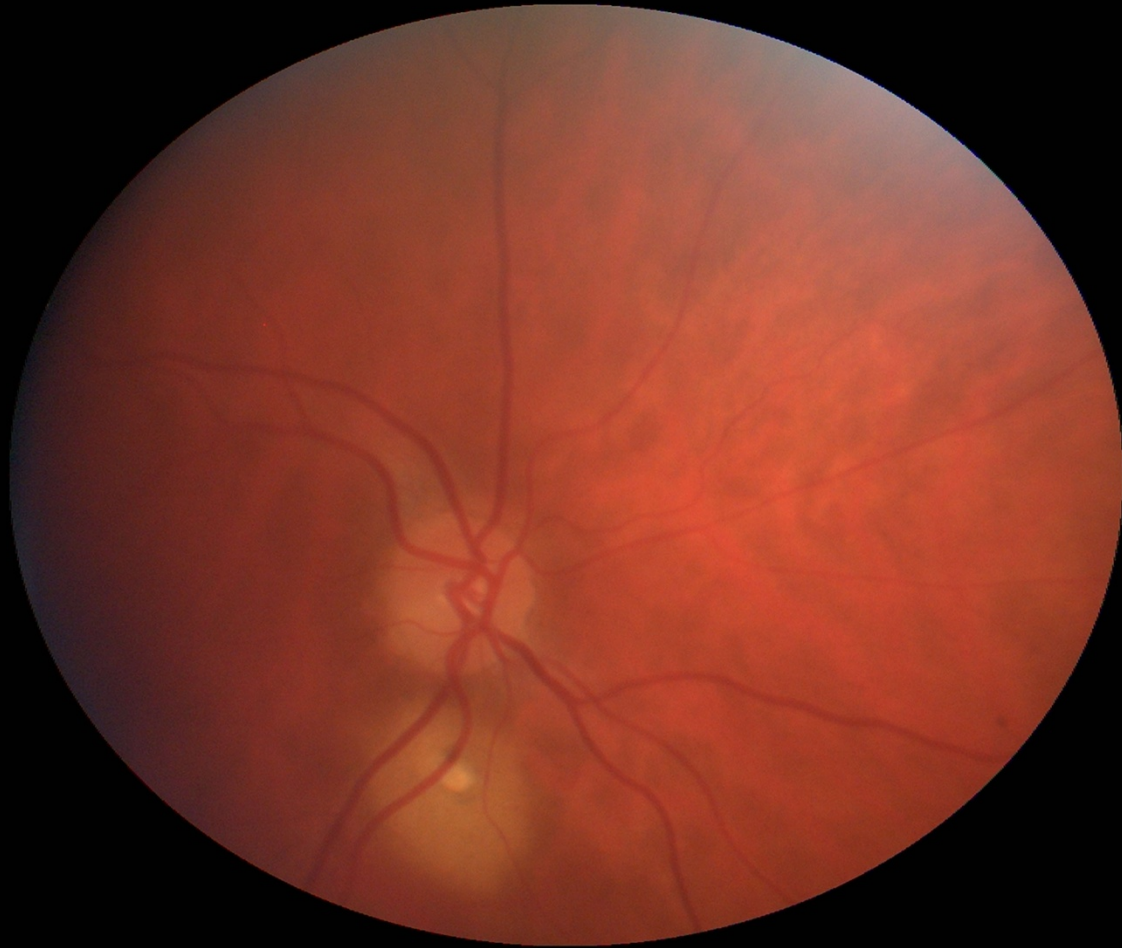
Hypertension



Glaucoma Suspect



Unknown Scar



Drusen At Macula

